

Full-Mouth Rehabilitation of a Patient with Gastroesophageal Reflux Disease: A Clinical Report

Juanli Guo, DMD, MS, PhD, FACP,¹ Glenn Reside, DMD,² & Lyndon F. Cooper, DDS, PhD, FACP³

¹Private Practice, Vienna, VA

²Department of Oral and Maxillofacial Surgery, School of Dentistry, University of North Carolina, Chapel Hill, NC

³Department of Prosthodontics, School of Dentistry, University of North Carolina, Chapel Hill, NC

Keywords

GERD; full-mouth rehabilitation; dental erosion; caries.

Correspondence

Juanli Guo, 8321 Old Courthouse Rd, Suite 120, Vienna, VA 22182. E-mail: ImplantDentalArt@gmail.com

Accepted August 18, 2011

doi: 10.1111/j.1532-849X.2011.00785.x

Abstract

Gastroesophageal reflux disease (GERD) is a chronic condition caused by stomach acid regurgitating into the esophagus or oral cavity, often causing heartburn. Tooth erosion and wear are common oral manifestations of GERD. This clinical report describes the full-mouth rehabilitation of a patient with over 30 years of GERD, causing wear of maxillary and mandibular anterior teeth, along with complications associated with past restorations. Full-mouth rehabilitation of natural teeth in conjunction with dental implants was selected as the treatment option. Ideal occlusal design and optimal esthetics, along with reinforcement of oral hygiene, ensure a favorable prognosis.

Patients with severely worn dentition frequently require full-mouth rehabilitation due to the associated occlusal discrepancy. It is critical to identify the etiology of the worn dentition before a proper treatment is initiated. The pathological loss of tooth structure can be caused by different processes: (1) abnormal attrition, loss of tooth structure, or restorative material due to tooth-tooth contact, such as bruxism; (2) abrasion, loss of tooth structure due to factors other than tooth contacts (brushing, tobacco chewing, etc.); and (3) erosion, chemical loss of tooth structure without bacteria involvement, usually demineralization of enamel or dentin by acid.¹ Based on the source of the acid, dental erosion can be differentiated into extrinsic erosion, where the acid is mainly from dietary consumption, or intrinsic erosion, where acid is mainly from gastric fluid, such as, in patients with bulimia or gastroesophageal reflux disease (GERD). The critical pH value of enamel (when it begins to dissolve) is around 5.2. The pH value of most acidic beverages and gastric fluid is below 2.0.² The cause of erosion sometimes can be differentiated based on the wear pattern. Intrinsic erosion generally occurs on the palatal surfaces of the maxillary anterior teeth and the mandibular posterior teeth.³ The prevalence of dental erosion in adult GERD patients has been documented to be around 25%.⁴ However, the correlation between GERD and the prevalence of dental caries appears to be negative or even a reverse relationship.⁵

This report focuses on a patient with a long history of GERD, and a presentation of tooth wear on the maxillary and the mandibular anterior teeth, along with heavily restored dentition and a failing five-unit fixed dental prosthesis (FDP).

Clinical report

Preoperative information, diagnosis, and treatment plan

A 58-year-old woman presented with the chief complaint of a loose FDP. She lacked self-confidence due to thin and unesthetic anterior teeth. A review of the patient's medical history revealed she had GERD for more than 30 years, and was taking an over-the-counter H2 blocker, Prevacid. She had a cholecystectomy and hysterectomy 1 year before her initial prosthodontic office visit, and was taking Progestin for hormonal replacement. She had a history of high blood pressure that was under control with medication (Terazosin). She had no known drug allergy. She did not smoke, and consumed alcohol occasionally. The patient had no medical contraindications to dental treatment.

Over the past 35 years, the patient had extensive dental treatment, including root canal treatment (RCT), fillings, crowns, and FDPs. The upper-left FDP had been loose for more than 6 months. Clinical exam revealed that a five-unit FDP on teeth #11 to 15 was loose. After removal of the FDP, abutment tooth #11 was noted to have deep caries below the gingival level and was determined nonrestorable. The patient also presented with moderately worn dentition and restorations. Defective composite restorations were present on most of the anterior teeth. Multiple fixed restorations were in place, including porcelain-fused-to-metal (PFM) crowns on teeth #4, 5, 7, 21, 22, 27, and 28, full-gold crowns on teeth #2 and #17, a 7/8 gold crown on tooth #3, a PFM-FDP on teeth #18 to 20, and a gold FDP with mesial retainer facial porcelain veneer on

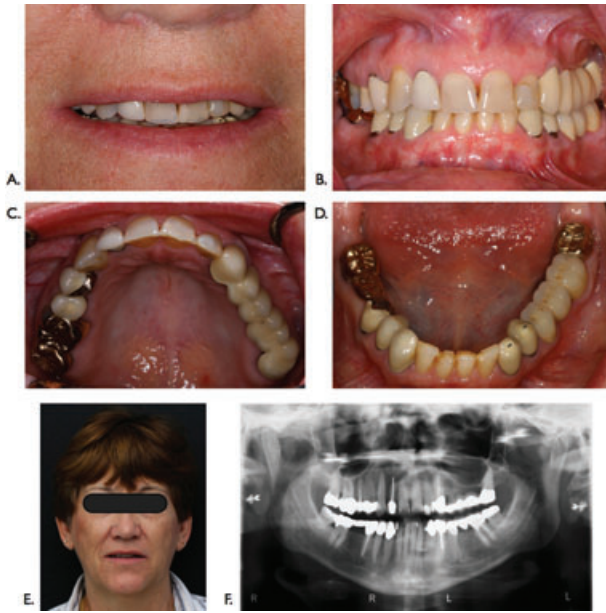

Figure 1 Preoperative images and panoramic radiograph. (A) Close-up frontal view showing thin maxillary incisors. Intraoral images: (B) Frontal view at maximum-intercuspal position (MIP); (C) Maxillary occlusal; and (D) Mandibular occlusal views. (E) Preoperative smile image. (F) Preoperative panoramic radiograph.

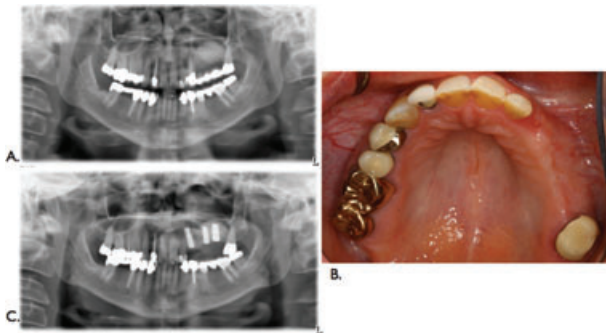


Figure 2 (A) Panoramic radiograph after the lateral window sinus augmentation. (B) Intraoral maxillary view after the sinus augmentation and the ridge augmentation. (C) Panoramic radiograph after implant placement.

#29 to 31. Secondary caries was noticed on teeth #2, 6, 8, 9, 10, 11, 17, 18, 20, and 29. The patient had an Angle’s Class I canine relationship and an Angle’s Class III molar relationship. The mandibular midline was coincident with the facial midline, whereas the maxillary midline was 2 mm to the left. The occlusal vertical dimension (OVD) was deemed reduced after evaluation of esthetics and phonetics. The patient’s centric occlusion and maximal intercuspal position (MIP) were coincident. Radiographic findings revealed generalized mild to moderate bone loss (Fig 1). Using the American College of Prosthodontists’ Prosthodontic Diagnostic Index (PDI) for partial edentulism, the patient was classified as Class IV.⁶

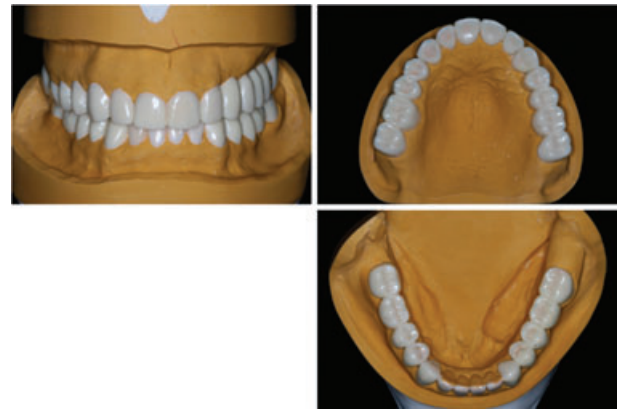


Figure 3 Diagnostic wax-up.

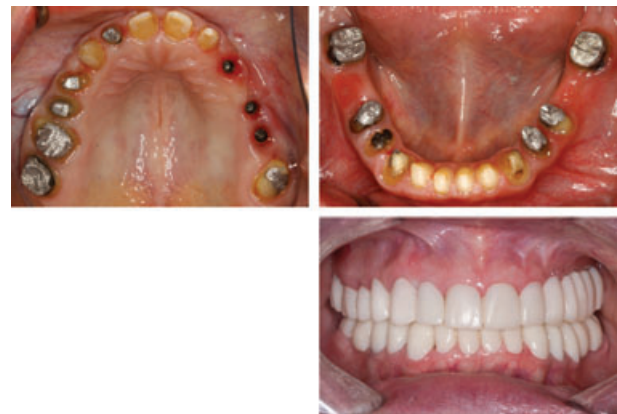

Figure 4 Tooth preparations and interim prostheses.

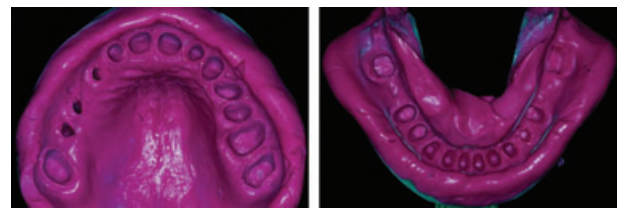


Figure 5 Final impressions.

The options of single implant versus 3-unit FDPs in the edentulous areas of #19 and #30 were discussed with the patient. She decided to have FDPs due to financial concerns. Maxillary anterior crown lengthening and orthodontic treatment to correct malocclusion before definitive prosthodontic treatment were also proposed to the patient, but were rejected.

Treatment procedures

A caries management program, including dietary assessment and reinforcement of oral hygiene measures, was initiated before the treatment was started. Periodontal treatment was completed before starting other treatment procedures. A lateral

window approach sinus floor augmentation was performed, and the grafted area was allowed to heal for 6 months before implant placement. Three months after sinus floor augmentation, the existing FDP #11 to 15 was sectioned at the mesial of abutment tooth #15. The nonrestorable tooth #11 was extracted, and ridge augmentation was completed. An interim PRDP was inserted during healing. After healing of the sinus floor augmentation and the ridge augmentation, three dental implants were placed at #11, 13, and 14 with the aid of a surgical guide (Fig 2).

A set of diagnostic casts was made and articulated on a Hanau Wide-View articulator (Waterpik Technologies, Fort Collins, CO) using a Hanau Springbow and a centric relation record. Diagnostic wax-up was done to plan the anticipated occlusion and to foresee any potential problems (Fig 3). OVD was restored by opening about 1.5 mm on the incisal guide pin to compensate the lost OVD.

During the healing of bone grafting and implant surgery, all defective restorations on teeth #6 to 10 and #23 to 26 were removed, and secondary caries excavated. The cavities were restored with composite resin. All existing crowns and FDPs were sectioned and removed. All abutment teeth were thoroughly examined, and secondary caries excavated. Tooth #17 had lost extensive tooth structure and was extracted due to nonpredictable RCT. Teeth #2 and 20 had lost extensive tooth structure, and were recommended to have selective RCT and dowel-core buildup before new crowns were fabricated. Teeth #3, 4, 18, 20, 21, and 31 did not have enough remaining coronal tooth structure for adequate ferrule effect. Therefore, crown-lengthening surgery was recommended. Teeth #3, 5, 15, 18, and 31 lost some tooth structure, but were determined to be restorable and have a favorable prognosis. They were restored with amalgam, with pins placed on teeth #3 and 31 to assist core retention. A cast dowel-core of tooth #21 became loose and was removed. Teeth #2, 4, 7, 20, 21, and 29 were recommended to have RCT. Dowel spaces were prepared on #2, 4, 7, 20, and 21 using a ParaPost XP System (Coltene Whaledent Inc, Cuyahoga Falls, OH). Prefabricated stainless steel ParaPosts was bonded with resin cement (MaxCem Resin Cement, Kerr Corporation, Orange, CA), and the teeth were then restored with amalgam. Tooth #29 had adequate tooth structure after RCT and was restored with amalgam. The preparations were refined. Provisional crowns and FDPs were fabricated using autopolymerized acrylic resin.

The implants were uncovered during second stage surgery after 3 months healing, and a screw-retained provisional FDP was fabricated at #11 to 13–14 area. Teeth #6 to 10 were prepared for zirconium-based all-ceramic crowns. Teeth #23 to 26 were prepared for Empress all-ceramic crowns (Ivoclar Vivadent, Amherst, NY). A set of new provisional crowns and FDPs was fabricated and delivered at the increased OVD (Fig 4). After the patient felt comfortable with the new interim prostheses for a month, impressions of the interim prostheses were made, and casts were poured (Fig 5). Casts were mounted on a Hanau Wide-View semi-adjustable articulator. A custom incisal guide table was fabricated. Final impressions were made of all prepared natural teeth and implant fixtures with vinylpolysiloxane (VPS) impression material. Centric relation interocclusal records, including preparation against prepara-

tion, and preparation against interim prostheses, were made with VPS material and the aid of a Lucia Jig, which was fabricated at the same OVD as the interim prostheses. Master casts were crossmounted against the casts of the interim prostheses. The interim prostheses were used to guide the fabrication of the final prostheses. In this case, computer-aided-design/computer-aided-manufacture (CAD/CAM) abutments were used for the implant-supported, cement-retained FDPs. The final prostheses were designed as follows: full-gold crowns on teeth #2 and #15; PFM crowns on teeth #3, 4, 5, 14, 21, and 28; PFM-FDPs on teeth/implants #11 to 13, 18 to 20 (#18 as full gold retainer), and 29 to 31 (#31 as full gold retainer); zirconium-based all-ceramic crowns (Lava, 3M ESPE, St. Paul, MN) on teeth #6 to 10, 22, and 27; and IPS Empress Esthetics (Ivoclar Vivadent, Amherst, NY) all-ceramic crowns on teeth #23 to 26. The occlusion was constructed as mutually protected occlusion with anterior guidance at protrusion and lateral excursion (Fig 6). The IPS Empress all-ceramic crowns were etched with hydrofluoric acid, conditioned with saline coupling agent, and bonded to the abutment teeth using light-polymerized resin cement (Variolink, Ivoclar Vivadent, Amherst, NY). The remaining crowns and FDPs were cemented using resin-modified glass ionomer (GC FujiCEM, GC America, Alsip, IL).

Posttreatment therapy and prognosis

One week after the final prostheses were delivered, the patient returned to the clinic for re-evaluation. A maxillary occlusal splint was delivered 2 weeks after the treatment. She was satisfied with the treatment and was very motivated to maintain the final prostheses with excellent oral hygiene practices. Oral hygiene instruction was reinforced throughout the treatment and after the treatment. The patient was placed on a 6-month recall schedule. The restoration of the patient's dentition, coupled with the development of an ideal occlusal scheme, excellent oral hygiene practices, and a positive attitude assures a favorable long-term prognosis.

Discussion

Multiple factors, including attrition, abrasion, and erosion, contribute to tooth wear. It has been well documented that GERD can cause dental erosion; however, whether there is a correlation between GERD and dental caries is not well known. It has been proposed that due to the strong acidity of gastric acid, GERD patients typically are less prone to dental caries, partly because of the inhibition effect of strong gastric acid on bacteria.⁵ However, dental caries is a multifactorial disease. The patient's dietary habits, intake of medicine, oral hygiene, history of dental treatment, and the predisposed tooth structure could also contribute to caries formation. In this patient, previous extensive dental treatment including tooth-colored (composite resin) restorations, crowns, and FDPs, instead of GERD itself, may have caused higher caries risk. In addition, the daily intake of multiple medicines and limited oral hygiene measures also increased the dental caries risk. It is not surprising for the patient to present with both secondary caries and dental erosion.

Management of dental erosion is mainly focused on preventive strategies; therefore, identifying the source of erosion

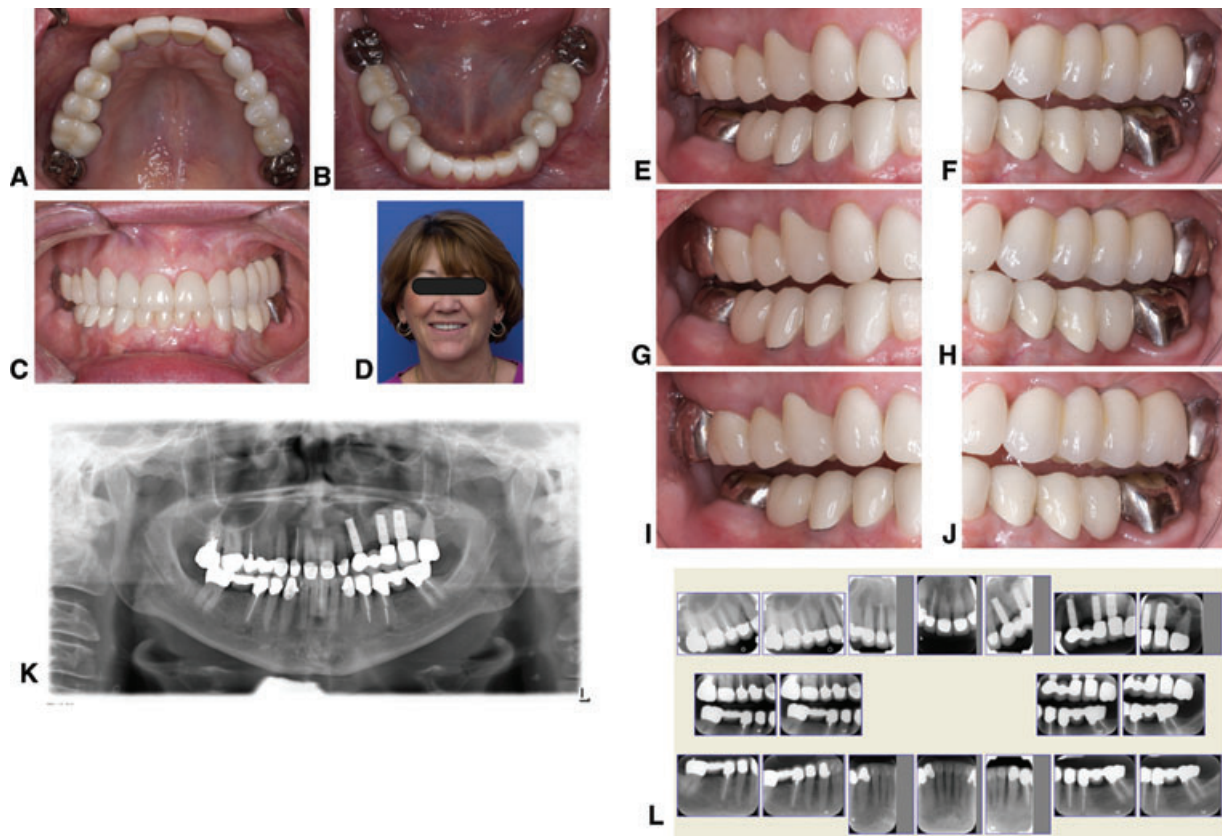


Figure 6 Postoperative images and radiographs. (A) Maxillary occlusal view. (B) Mandibular occlusal view. (C) Frontal view at MIP. (D) Patient's facial frontal smile view. (E, F) Lateral view at protrusion. (G, H) Lateral view at laterotrusion. (I, J) Lateral view at mediotrusion. (K) Postoperative panoramic radiograph. (L) Postoperative full-mouth series radiograph.

is very important. These strategies include: (1) to identify the source of erosive tooth wear; (2) to refer to a physician if it is intrinsic erosion; (3) to reduce acid intake; (4) to reduce the level of oral acidity; (5) to increase salivary flow; (6) to remineralize the eroded areas; (7) to reduce abrasion; (8) to protect the exposed dentin with resin restorations or lingual veneers; (9) to fabricate an occlusal night guard.⁷ When restoration is necessary, it is recommended to be conservative when the erosion is not accompanied with occlusal discrepancy or reduced OVD.⁸ Based on the severity of erosion, choices of restoration could range from sealants to composite restorations to indirect restorations, such as inlays, onlays, and crowns. In severe cases, when there is occlusal discrepancy and reduced OVD, full-mouth rehabilitation is often indicated.

In this case, the patient had previous restorations with an occlusal plane discrepancy and occlusal interference. Full-mouth rehabilitation was indicated. The moderately worn palatal surfaces of the maxillary anterior teeth and the worn and lingually inclined mandibular anterior teeth make it challenging to restore the dentition at the preoperative OVD. Due to the loss of palatal tooth structure on maxillary anterior teeth and lingual inclination of mandibular anterior teeth, minimal preparation on the palatal surfaces of maxillary anterior teeth and facial surfaces of mandibular anterior teeth was indicated. Subgin-

gival margins were indicated in this case to prevent future erosion of tooth structures due to GERD. When considering cement selection, there are no guidelines available to compare the solubility and biomechanical behaviors of different cements in an acidic environment; however, it has been reported when cement materials, such as glass ionomer, resin-modified glass ionomer, and composite resin, are used as restorative materials, they are more resistant to erosive wear when compared to enamel. Differences have been reported among restorative materials, with glass ionomer most susceptible to acid, resulting in lower erosive wear resistance and microhardness, and composite resin the most resistant to acid.^{9,10} For this patient, composite resin was used to bond the anterior restorations due to its higher acidic resistance and stronger bonding strength. Resin-modified glass ionomer was used to cement the other restorations due to its lower technique sensitivity and reasonable acidic resistance.

References

1. Eccles JD: Tooth surface loss from abrasion, attrition, and erosion. *Dent Update* 1982;9:373-381
2. Larsen MJ: Chemical events during tooth dissolution. *J Dent Res* 1990;69(spec Issue):575-580

3. Bartlett DW, Evans DF, Anggiansah A, et al: A study of the association between gastro-oesophageal reflux and palatal dental erosion. *Br Dent J* 1996;181:125-131
4. Pace F, Pallotta S, Tonini M, et al: Systematic review: gastro-oesophageal reflux disease and dental lesions. *Aliment Pharmacol Ther* 2008;27:1179-1186
5. Munoz JV, Herreros B, Sanchiz V, et al: Dental and periodontal lesions in patients with gastro-oesophageal reflux disease. *Dig Liver Dis* 2003;35:461-467
6. McGary TJ, Nimmo A, Skiba JF, et al: Classification system for partial edentulism. *J Prosthodont* 2002;11:181-193
7. Donovan T: Dental erosion. *J Esthet Restor Dent* 2009;21:359-364
8. Reis A, Higashi C, Loguercio AD: Re-anatomization of anterior eroded teeth by stratification with direct composite resin. *J Esthet Restor Dent* 2009;21:304-316
9. Shabanian M, Richards LC: In vitro wear rates of materials under different loads and varying pH. *J Prosthet Dent* 2002;87:650-656
10. Honorio HM, Rios D, Francisconi LF, et al: Effect of prolonged erosive pH cycling on different restorative materials. *J Oral Rehabil* 2008;35:947-953